

Validating tractography from DWI/SWI data with 3D reconstructed histological data of post-mortem human brain tissue

K.J. Sikma^{1,2}, M. Kleinnijenhuis^{1,3}, M. Barth³, P.J. Dederen¹, B. Küsters⁴, C.H. Slump², A.M. van Cappellen van Walsum^{1,2}

¹Department of Anatomy, Radboud University Nijmegen Medical Centre, ²MIRA Institute for Biomedical Technology and Technical Medicine, University of Twente,

³Donders Institute for Brain, Cognition and Behaviour, Radboud University Nijmegen, ⁴Department of Pathology Radboud University Nijmegen Medical Centre

Introduction

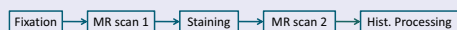
Diffusion weighted imaging (DWI) uses diffusion anisotropy to obtain unique clues about the structure and organization of brain tissue like the specific organization of the myelinated axonal fibers in white matter. A problematic area in DWI tractography concerns the grey-white matter (GMWM) boundary of the cortex, where multiple directions in a voxel cannot be resolved due to multiple fiber orientations within one voxel (see Figure 1). This poster presents a pilot, part of a research project which aims to see if information obtained by susceptibility weighted images (SWI) can be used to aid tractography. This will be validated by a 3D reconstruction of histological data.

Aim

This study is a pilot which evaluates a staining method adapted from Blackwell et al. (Blackwell et al., NI 2009). This staining is thought to enhance MR contrast of myelinated and unmyelinated tissues due to paramagnetic properties of the dye. The aim is to optimize scanning and staining procedures in order to validate DWI/SWI data with histological data.

Methods

The following steps were performed during the experiments:



Fixation: Human brain tissue samples (1x1x3 cm) were obtained post mortem by dissecting gyri, containing both the cortex and underlying white matter. The dissected tissue was fixed in formaldehyde. The post-mortem interval at the time of dissection was <24 h.

MR: Multi-echo gradient-echo images (MGRE) of the tissue samples were acquired on a 7T Bruker ClinScan system with 290 mT/m gradient set. A 3D FLASH sequence was used (TR=45 ms; TE=5.3/13.7/22.0/30.4/38.8 ms; flip angle=25°; BW 140 Hz/px) acquiring 160 slices (FOV=120x120 mm; matrix size=512x512; slice thickness=250 μm) yielding a near-isotropic resolution of 234x234x250 μm. The total scan time amounted to 13 h (for 13 acquisitions).

Staining: The staining of the tissue samples was done *en bloc* with Luxol Fast Blue (LFB), which preferentially stains myelinated nerve fibers. The paramagnetic properties of LFB influence the MR signal of the stained tissue, potentially enhancing contrast between of myelinated and unmyelinated tissues.

Histological processing: The stained tissue samples were cut in sections of 50 to 100 μm. These sections were imaged with a Zeiss microscope mounted with a motorized stage, controlled by MicroBrightField (MBF) software. Histological images were taken at 20x magnification and higher. Using the Virtual Slice module in the MBF software, the high resolution images were combined to reconstruct the imaged sections.

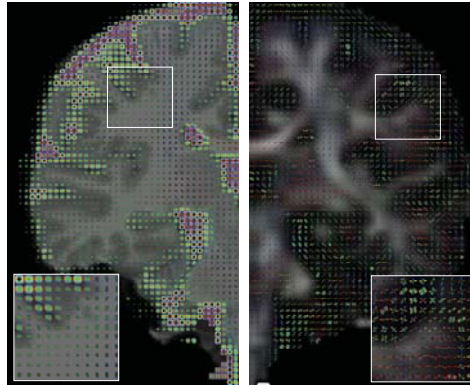


Figure 1: Whole brain coronal MRI view. *Left:* T1 MRI with diffusion tensors. *Right:* Fractional Anisotropy MRI with Persistent Angular Structure (PAS) reconstructions. Limited anisotropy is present in the gray matter (outside dark gray layer), resulting in isotropic diffusion tensors in the gray matter regions.

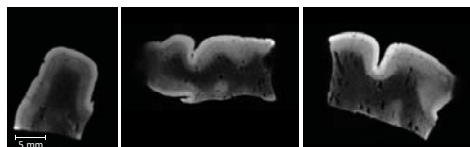


Figure 2: Orthogonal views of a single acquisition MGRE (TE=22.0 ms) volume of a brain tissue sample before staining. Acquired with the 7T scanner. White and gray matter can be distinguished. Some cortical layers are also visible.




Figure 3: A virtual slice image at 20x magnification of LFB stained tissue of a 100 μm thick section. Directionality of myelinated axons is clearly visible in the white/gray matter interface. The shades of blue represent different regions in the tissue: white matter (WM) and grey matter (GM). Because LFB stains myelin, the WM has a darker shade of blue because it contains a huge amount of myelinated nerve fibers. The GM is stained less because there is hardly any myelin present.

Results

Scans with the 7T scanner showed excellent detail and contrast between gray and white matter in the MGRE scans. Even with the current resolution layers in the cortex could also be seen clearly.

Results of single sections which were stained with our newly developed protocol, showed that directionality of myelinated fibers traversing the GMWM boundary could microscopically be observed (see Figure 3). Staining the samples according to the specifications of Blackwell et al. did not result in a thorough stained and differentiated sample. Both staining and differentiation took significantly longer than described. Because the MR scanned samples were not stained optimally, the effect of LFB on the MR scans could not be investigated yet.

Conclusions

Gradient-echo images of fixed tissue samples acquired with the 7T MR scanner show superb contrast between gray and white matter and between cortical layers in magnitude images (Figure 2) and phase images (not shown).

After successfully staining the brain tissue samples with LFB, the directionality of cortical fibers is clearly visible in the imaged sections (Figure 3). Although DWI, SWI and histological data in the same sample are not available yet, this would allow validation of ultrahigh resolution cortical DWI/SWI data to histological information.

With the promising results obtained in the present pilot, validation of DWI data will be possible. Next steps already being pursued are obtaining DWI/SWI data of stained brain tissue samples and reconstructing the high resolution imaged histological sections to a 3D volume.

Acknowledgements

This research is done in context of the VIP Brain Networks project.

VIP Brain Networks

